



Tibialis posterior dysfunction: a common and treatable cause of adult acquired flatfoot

Julie Kohls-Gatzoulis, John C Angel, Dishan Singh, Fares Haddad, Julian Livingstone and Greg Berry

BMJ 2004;329:1328-1333
doi:10.1136/bmj.329.7478.1328

Updated information and services can be found at:
<http://bmj.com/cgi/content/full/329/7478/1328>

These include:

Data supplement

"A film showing left sided tibialis posterior dysfunction"
<http://bmj.com/cgi/content/full/329/7478/1328/DC1>

References

1 online articles that cite this article can be accessed at:
<http://bmj.com/cgi/content/full/329/7478/1328#otherarticles>

Rapid responses

One rapid response has been posted to this article, which you can access for free at:
<http://bmj.com/cgi/content/full/329/7478/1328#responses>

You can respond to this article at:
<http://bmj.com/cgi/eletter-submit/329/7478/1328>

Email alerting service

Receive free email alerts when new articles cite this article - sign up in the box at the top left of the article

Topic collections

Articles on similar topics can be found in the following collections

[General practice / family medicine](#) (2299 articles)
[Immunology \(including allergy\)](#) (2676 articles)
[Pain \(neurology\)](#) (1102 articles)
[Inflammation](#) (235 articles)
[Biological agents](#) (196 articles)
[Degenerative joint disease](#) (336 articles)
[Drugs: musculoskeletal and joint diseases](#) (848 articles)
[Musculoskeletal syndromes](#) (623 articles)
[Trauma](#) (544 articles)
[Internet](#) (428 articles)
[Injury](#) (518 articles)

Notes

To order reprints follow the "Request Permissions" link in the navigation box

To subscribe to *BMJ* go to:
<http://resources.bmj.com/bmj/subscribers>

Clinical review

Tibialis posterior dysfunction: a common and treatable cause of adult acquired flatfoot

Julie Kohls-Gatzoulis, John C Angel, Dishan Singh, Fares Haddad, Julian Livingstone, Greg Berry

Royal National
Orthopaedic
Hospital, Stanmore
HA7 4LP

Julie
Kohls-Gatzoulis
*specialist registrar
orthopaedic and
trauma surgery*

John C Angel
*consultant
orthopaedic surgeon*

Dishan Singh
*consultant
orthopaedic surgeon*

Middlesex Hospital,
London W1N 8AA
Fares Haddad
*consultant
orthopaedic surgeon*

Barnet General
Hospital, Barnet
EN5 3DJ

Julian Livingstone
podiatrist

McGill University
Health Centre,
Hôpital Général de
Montréal 1650,
Avenue Cedar,
Montreal, Canada
H3G 1A4

Greg Berry
*consultant
orthopaedic surgeon*

Correspondence to:
J Kohls-Gatzoulis
gatzoulis@
ntlworld.com

BMJ 2004;329:1328-33

Adults with an acquired flatfoot deformity may present not with foot deformity but almost uniformly with medial foot pain and decreased function of the affected foot (for a list of causes of an acquired flatfoot deformity in adults, see box 1).¹ Patients whose acquired flatfoot is associated with a more generalised medical problem tend to receive their diagnosis and are referred appropriately. However, in patients whose “adult acquired flatfoot deformity” is a result of damage to the structures supporting the medial longitudinal arch, the diagnosis is often not made early.² These patients are often otherwise healthier and tend to be relatively more affected by the loss of function resulting from an acquired flatfoot deformity. The most common cause of an acquired flatfoot deformity in an otherwise healthy adult is dysfunction of the tibialis posterior tendon, and this review provides an outline to its diagnosis and treatment.

Sources and selection criteria

We searched PubMed for publications by using the keywords “flatfoot” and “tibialis posterior dysfunction”.

Tibialis posterior dysfunction: a common condition

Tibialis posterior dysfunction is well recognised by orthopaedic surgeons specialising in foot and ankle surgery and by podiatrists. However, greater general awareness of this condition is required,² as most patients presenting to a general practitioner receive a diagnosis of ankle sprain or arthritis. By the time most patients present to a specialist foot and ankle clinic they have had the condition for several years and have consulted numerous doctors.³ Even general orthopaedic surgeons and physiotherapists often miss the diagnosis.³ However, tibialis posterior dysfunction need not remain a “specialist diagnosis” as it is usually diagnosed without any investigations, from a history and physical examination.² Many patients benefit from relatively simple treatment, such as orthotic devices.⁴ Population based studies to identify the prevalence of tibialis posterior dysfunction are under way. In elderly people the condition may reach a prevalence of 10% in women⁵ and it is often seen in general practice (unpublished data).

Tibialis posterior tendon: the key dynamic support of the medial longitudinal arch of the foot

Understanding the importance of the tibialis posterior tendon for the normal foot clarifies the role that the

Summary points

Dysfunction of the tibialis posterior tendon is a common condition and a common cause of acquired flatfoot deformity in adults

Women older than 40 are most at risk

Patients present with pain and swelling of the medial hindfoot. Patients may also report a change in the shape of the foot or flattening of the foot

The foot develops a valgus heel (the heel rotates laterally when observed from behind), a flattened longitudinal arch, and an abducted forefoot

Conservative treatment includes non-steroidal anti-inflammatory drugs, rest, and immobilisation for acute inflammation; and orthoses to control the more chronic symptoms

Surgical treatment in the early stages is hindfoot osteotomy combined with tendon transfer

Arthrodesis of the hindfoot, and occasionally the ankle, is required in the surgical treatment of the later stages of tibialis posterior dysfunction

dysfunctional tibialis posterior has in the development of an acquired flatfoot. This tendon courses just posterior to the medial malleolus inserting into the navicular tuberosity (on the medial aspect of the foot) and the mid-part of the plantar aspect of the tarsus. The tibialis posterior tendon is the primary dynamic stabiliser of the medial longitudinal arch,⁶ and its contraction results in inversion and plantar flexion of the foot and serves to elevate the medial longitudinal arch, which locks the mid-tarsal bones, making the hindfoot and midfoot rigid.⁷ This later action allows the gastrocnemius muscle to act with much greater efficiency during gait. Without the tibialis posterior, the other ligaments and joint capsules gradually become weak,



A film showing left sided tibialis posterior dysfunction is on bmj.com. Please note that the file is very large, so you will probably need broadband to watch this film

Box 1: Causes of an adult acquired flatfoot

- Neuropathic foot (Charcot foot) secondary to:
 - Diabetes mellitus
 - Leprosy
 - Profound peripheral neuritis of any cause
- Degenerative changes in the ankle, talonavicular or tarsometatarsal joints, or both, secondary to:
 - Inflammatory arthropathy
 - Osteoarthropathy
 - Fractures
- Acquired flatfoot resulting from loss of the supporting structures of the medial longitudinal arch:
 - Dysfunction of the tibialis posterior tendon
 - Tear of the spring (calcaneonavicular) ligament (rare)
 - Tibialis anterior rupture (rare)

Painful flatfoot can have other causes, such as tarsal coalition, but as such a patient will not present with a change in the shape of the foot these are not included here.

Box 2: Symptoms suggesting tibialis posterior dysfunction

- Pain and/or swelling behind the medial malleolus and along the instep
- Change in foot shape
- Decrease in walking ability and balance
- Ache on walking long distances

and thus flatfoot develops. Furthermore, without the tibialis posterior the gastrocnemius is unable to act efficiently, and therefore gait and balance are seriously affected.

Pathogenesis

Histological examination has shown that, rather than tendinitis (tendon inflammation), the process is one of tendinosis (tendon degeneration), and the tibialis posterior tendon becomes fibrotic through a process of repeated microtrauma.⁸ Some controversy remains about the underlying aetiology of this tendinosis.⁹⁻¹⁵ A poor blood supply to the tendon has been identified as it courses posterior to the medial malleolus.⁹ Mechanical factors must be at play that predispose the tendon to progressive fibrosis.¹⁰ A growing body of research proposes that abnormal forces arise from even mild flatfootedness, resulting in lifelong greater mechanical demands on the tibialis posterior than in a normal foot.¹¹⁻¹⁴ Another possible mechanical aetiology is overpull of the opposing peroneus brevis muscle.¹⁵ Rarely, rupture of the tibialis posterior tendon has also been associated with a traumatic event such as ankle fracture,¹⁶ ankle sprain,¹⁷ or a direct blow to the tendon.¹⁸ It is important to point out that, although the tibialis posterior tendon may rupture, this is not necessary for tibialis posterior dysfunction to develop.¹⁰ Likewise, iatrogenic loss of the tibialis posterior tendon does not always lead to an acquired flatfoot deformity.^{14 15}

Risk factors

Middle aged women are most commonly affected, and the prevalence is known to increase with age.^{19 20} Pes planus (flatfoot),¹¹⁻¹⁴ hypertension,¹⁹ diabetes mellitus,¹⁹ steroid injection around the tendon,⁷ and seronegative arthropathies^{7 21} have all been identified as risk factors in patients with insufficiency of the tibialis posterior tendon.

Classification

Johnson and Strom's classification describes the progression of tibialis posterior dysfunction, and also serves as a guide to management.²² In stage I dysfunction, the tendon is still intact and to some degree functioning, but it is inflamed. In stage II dysfunction, the tendon has become dysfunctional and the foot has developed acquired flatfoot, but the deformity is passively correctable. In stage III dysfunction, the foot deformity has become fixed, and degenerative changes are seen in the subtalar joint. Stage IV was not described by Johnson and Strom but has been added subsequently by Myerson.⁷ Stage IV dysfunction occurs when degenerative changes are also present in the ankle joint.

Diagnosing tibialis posterior dysfunction**History**

In stage I, patients typically present with an insidious onset of vague pain in the medial foot and swelling behind the medial malleolus along the course of the tendon (fig 1).⁵ Patients usually have no history of acute trauma. As the condition progresses to stage II, patients have more complaints related to loss of function and change in the shape of the foot. They report either a unilateral worsening of a pre-existing bilateral flatfoot or a newly acquired flatfoot deformity.²² We tested survey questions and found that medial pain or swelling behind the medial malleolus together with a change in foot shape picked up 100% of patients with tibialis posterior dysfunction and had a specificity of 98% (box 2).⁵ Also the patient may have a feeling of instability, a limp, a restricted walking distance, and an inability to walk on uneven surfaces. This also leads to an increased awareness of other foot pathologies, such as bunions, hallux rigidus, and metatarsalgia, which may be the reason why the patient seeks medical atten-

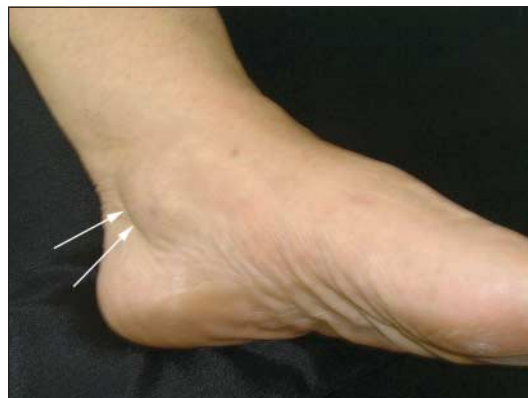

Fig 1 Arrows indicate swelling along the tibialis posterior tendon

Box 3: Definitions

Valgus: Angulation of an extremity at a joint or fracture site such that the distal part deviates away from the midline

Varus: Angulation of an extremity at a joint such that the distal part deviates toward the midline

tion. In the later stages, as the flatfoot deformity worsens, patients have less medial pain and swelling and may even have lateral hindfoot pain secondary to impingement of the fibula on the sinus tarsi.²⁰

Examination

In stage I tibialis posterior dysfunction the signs are of swelling and tenderness behind and below the medial malleolus (along the course of the tendon), and some weakness or pain with inversion of the foot (fig 2).² The patient may have some difficulty rising on one heel only, or weakness after multiple heel rises.^{7 20}

In the later stages the patient may have less swelling and pain but will have developed an acquired flatfoot deformity.² Looking at the standing patient from the back best shows the asymmetry of a unilateral acquired flatfoot deformity (fig 2). The affected heel is in a valgus position (box 3), and flattening of the medial longitudinal arch and forefoot abduction are visible. This leads to the commonly quoted “too many toes sign” where more than the normal (one and a half to two) toes are seen along the lateral border of the foot.² In later stages the tendon may not be palpable at its insertion site (the navicular tuberosity)¹; this is best assessed with the patient attempting to invert and point the foot downwards. The most commonly applied functional test is the single heel rise (fig 3)²; patients with tibialis posterior dysfunction are unable to perform an ipsilateral unsupported single heel rise (to go from a flatfooted stance to standing on only the toes of their affected foot).

Someone with a normal foot can perform a single heel rise eight to 10 times, but by stage II patients are unable (or barely able) to perform a single unsupported heel rise. Even if the patient is supported to facilitate the attempted heel rise, the heel will not invert as it normally does (fig 3).¹⁶ In stages III and IV, in addition to the findings in stage II, the flatfoot deformity has become fixed. This is examined by grasping the heel and attempting to correct the valgus of the hindfoot (box 4).

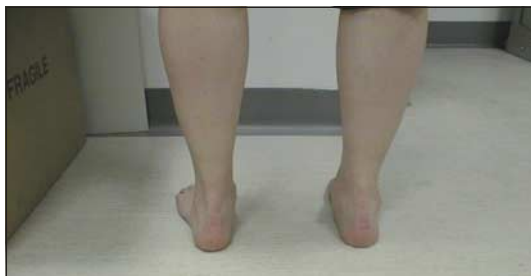

Fig 2 Left tibialis posterior dysfunction deformity is easily visible. The medial longitudinal arch is flattened. The left heel is in valgus. Also visible is the “too many toes sign,” which results from abduction of the left forefoot

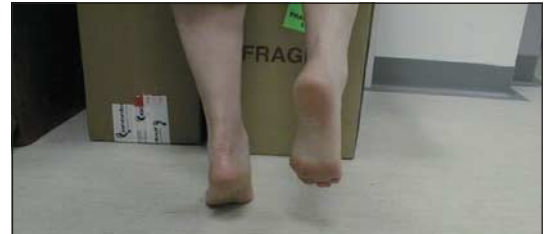
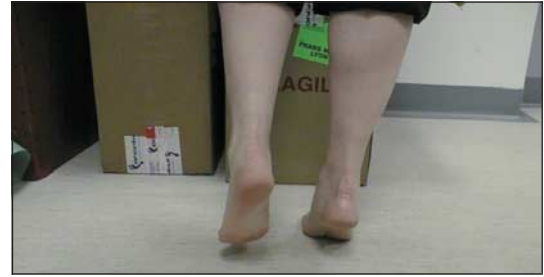
Fig 3 (top) Unsupported single heel rise on patient's good (right) side. (bottom) Attempt to perform a single heel rise on the affected left side. The patient was unable to do so unsupported but for the purpose of this photo was allowed to lean forward and support herself on the counter in front of her. The heel of the left foot has not inverted into varus

Imaging

The diagnosis of tibialis posterior dysfunction is essentially clinical. However, plain radiographs of the foot and ankle are useful for assessing the degree of deformity and to confirm the presence or absence of degenerative changes in the subtalar and ankle articulations. The radiographs are also useful to exclude other causes of an acquired flatfoot deformity.¹ The

Box 4: How to examine for tibialis posterior dysfunction

- (1) Both of patient's legs visible from knee down
- (2) Observe heel alignment with patient standing with feet shoulder width apart, feet parallel. (Heel becomes valgus, arch collapses, and forefoot adducts in cases of tibialis posterior dysfunction)
- (3) Inspect for swelling behind medial malleolus
- (4) Ask patient to stand on tiptoes. Normally the heel should bend inwards. A patient with tibialis posterior dysfunction will have great difficulty standing on tiptoes, and the heel will not bend inwards
- (5) Ask the patient to perform 10 unsupported heel rises on each leg. A patient with tibialis posterior dysfunction will not be able to do this
- (6) Palpate along the tibialis posterior tendon for tenderness
- (7) Test tibialis posterior tendon for power. Ask the patient to bring foot into an inverted and plantar flexed position from an everted and dorsiflexed position against your resistance
- (8) Examine for hindfoot movement. In stages I and II, the foot is supple and the flatfoot deformity can be corrected by rotating the heel inwards (the arch of the foot will be reconstituted). In stage III and IV subtalar arthritis is present, and movement of the subtalar joint will be lessened and painful. Additionally in stage IV, ankle arthritis has set in and the ankle becomes stiff and painful

Stages of tibialis posterior dysfunction and treatment options

Stage	Description	Conservative treatment	Surgical treatment
Stage I	Tendon inflamed No change in foot shape	Acute: 4-8 weeks' immobilisation; rest, ice, compression, and elevation (RICE); non-steroidal anti-inflammatory drugs (NSAIDs) Chronic: lace-up, flat footwear and corrective orthosis (off the shelf, University of California Biomechanics Laboratory (UCBL) or ankle foot orthosis (AFO))	Tendon debridement combined with corrective osteotomy
Stage II	Tendon elongated Acquired flatfoot deformity	Acute: 4-8 weeks' immobilisation, RICE, NSAIDS Chronic: lace-up, flat footwear and corrective orthosis (UCBL or AFO)	Tendon transfer and corrective osteotomy
Stage III	Fixed deformity Degenerative changes at subtalar joint	Lace-up, semirigid shoes or customised footwear and accommodative orthosis (AFO)	Triple arthrodesis (subtalar, calcaneo-cuboid, and talonavicular articulations)
Stage IV	Fixed deformity Degenerative changes at subtalar and ankle joints	Lace-up, semirigid shoes or customised footwear and accommodative orthosis (AFO)	Pantalar arthrodesis (subtalar, calcaneo-cuboid, talonavicular, and ankle articulations)

most useful radiographs are bilateral anteroposterior and lateral radiographs of the foot and a mortise (true anteroposterior) view of the ankle. All radiographs should be done with the patient standing (figs 4, 5).²⁰ In most cases we see no role for magnetic resonance imaging or ultrasonography, as the diagnosis can be made clinically.

Treatment

Conservative treatment

Conservative treatment is indicated for nearly all patients initially before surgical management is considered.⁴ The key factors in determining appropriate treatment are whether acute inflammation and whether the foot deformity is flexible or fixed. However, the ultimate treatment is often determined

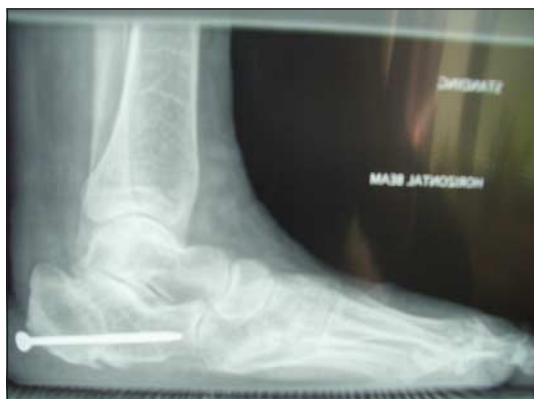
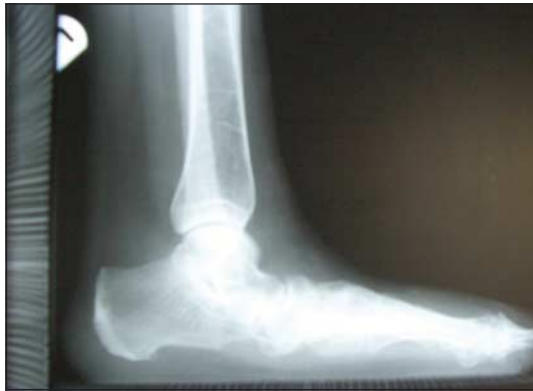
Fig 4 Before surgery (top) and five years after surgery (bottom) for a patient with stage II tibialis posterior dysfunction. The surgical reconstruction included a Cobb split tibialis anterior tendon transfer and a Rose varus calcaneal osteotomy

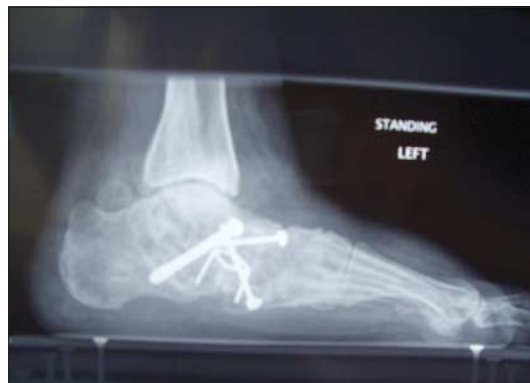
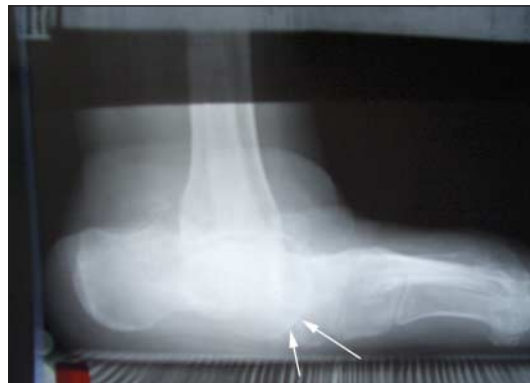
Fig 5 Stage III tibialis posterior dysfunction before and after surgery (a triple arthrodesis). (top) Preoperative film shows a plantar flexed talus (arrows point to head of talus) and loss of arch contour and height. (bottom) Postoperative film shows union and reconstitution of the arch

by the patients, most of whom are women aged 40 or older. Compliance can be a problem, especially in stages I and II. It helps to emphasise to the patients that tibialis posterior dysfunction is a progressive and chronic condition and that several fittings and a trial of several different orthoses or treatments are often needed before a tolerable treatment is found.

Stages I and II: the flexible foot

Any acute inflammation surrounding the sheath of the tibialis posterior tendon should be dealt with before the chronic aspect of the condition is treated. A period of four to eight weeks of immobilisation in a plaster cast below the knee or a removable boot (such as those made by Aircast) may be required to control accompanying inflammation.^{7 20 23} In conjunction, RICE (rest, ice, compression, and elevation) and anti-

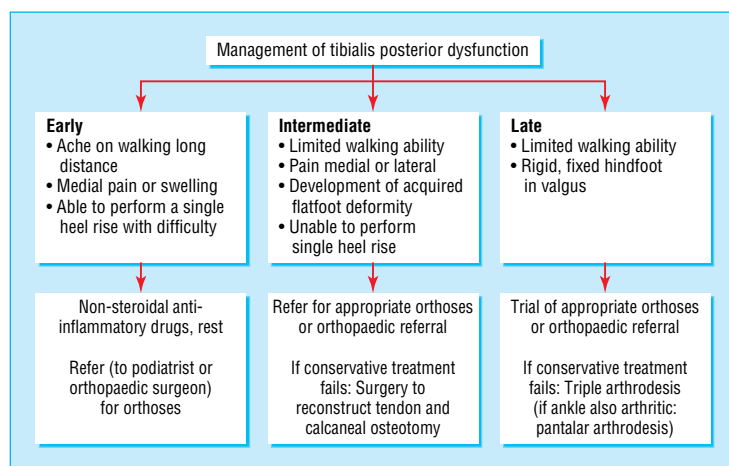


Fig 6 Treating tibialis posterior dysfunction

inflammatories can be used, but steroid injection is contraindicated.⁷

Footwear has an important role, and patients should be encouraged to wear flat lace-up shoes, or even lace-up boots, which accommodate orthoses. Stage I patients may be able to manage with an off the shelf orthosis (such as an Orthaheel or Formthotics). They can try a laced canvas ankle brace before moving to a casted orthosis. The various casted, semirigid orthoses support the medial longitudinal arch of the foot and either hold the heel in a neutral alignment (stage I) or correct the outward bent heel to a neutral alignment (stage II). This approach is meant to serve several functions: to alleviate stress on the tibialis posterior; to make gait more efficient by holding the hindfoot fixed; and thirdly, to prevent progression of deformity.²³ Devices available to do this are the orthosis of the University of California Biomechanics Laboratory, an ankle foot orthosis, or a removable boot. When this approach has been used, two thirds of patients have good to excellent results.⁴

Stage III and IV: the rigid flatfoot

Overall, inflammation tends to be a less common feature of presentation with the rigid acquired flatfoot. Treatment revolves around accommodating the

Resources for patients and doctors

www.footcaremd.com—Designed for patients and run and maintained by the American Orthopaedic Foot and Ankle Society. The information about tibialis posterior dysfunction can be found under the heading “progressive flat foot”

www.bofss.org.uk—Designed for both patients and doctors and is run by the British Orthopaedic Foot Surgery Society and gives good general advice about foot care

www.orthoteers.co.uk—A good site for doctors. Click on flatfeet (in the paediatrics section) and then on tibialis posterior insufficiency

www.rcsed.ac.uk/fellows/jbarrie/hyperbook—The website for the *Blackburn Foot and Ankle Hyperbook*. Clicking on “elective foot and ankle problems” and then on “tibialis posterior insufficiency” links you to a comprehensive list of causes, complaints, examinations, and stages

deformity (rather than attempting to correct it) with customised moulded rigid orthoses, used in conjunction with appropriate footwear (often custom made), as the foot deformity worsens.

Surgical treatment

Good to excellent results for more than 80% of patients have been reported at five years’ follow up for the surgical interventions recommended below.^{7 20} However, the postoperative recovery is a lengthy process, and most surgical procedures require patients to wear a plaster cast for two to three months. Although many patients report that their function is well improved by six months, in our experience a year is required to recover truly and gain full functional improvement after the surgery. Clearly, some patients are not candidates for such major reconstructive surgery.

Stage I—In individuals with notable flatfoot whose symptoms do not resolve with conservative measures, a calcaneal osteotomy may be considered. This aims to correct the underlying foot deformity, to attempt to preserve the foot’s function,⁷ in conjunction with either surgical debridement of the tendon²⁴ or tendon transfer.

Stage II—Consensus is growing that surgical treatment should entail tendon transfer in combination with corrective osteotomy.^{7 22} The rationale behind this approach is that the osteotomy is required to correct the bony architecture of the foot in order to optimise the biomechanics of the reconstructed tibialis posterior tendon. Various osteotomies of the calcaneus can correct the bony alignment^{7 22 25} and may be augmented with a lengthening of the lateral column. The tendons used to reconstruct tibialis posterior are either a split tibialis anterior tendon (fig 4) or flexor digitorum longus.

Stage III—The goal of surgical treatment is to correct the deformity and alleviate pain through a triple arthrodesis of the subtalar, calcaneocuboid, and talonavicular articulations (fig 5).

Stage IV—This has been reached when additional degenerative changes are present in the ankle joint. The salvage treatment at this stage is usually a pantalar arthrodesis (ankle, subtalar, calcaneocuboid, and talonavicular articulations).

Conclusions

The tibialis posterior muscle is the key dynamic support of the medial longitudinal arch of the foot. When it fails progressively, the arch slowly collapses, the heel drifts into valgus, and the forefoot gradually abducts, resulting in painful acquired flatfoot. Tibialis posterior dysfunction is often misdiagnosed as a chronic ankle sprain, osteoarthritis, or collapsed arch as a result of ageing or obesity, and it leaves the patient debilitated. Prompt diagnosis prevents frustration for the patient and allows treatment to be started at an earlier, more easily managed stage (fig 6). The diagnosis of tibialis posterior tendon dysfunction is largely a clinical one. An increased awareness of the existence of tibialis posterior should serve to help patients with earlier referral and treatment and by limiting the amount of disability they experience.

Contributors: JK-G wrote the paper. JL gave podiatric advice. FH and GB are involved in collaborative research on tibialis posterior dysfunction and have worked with senior authors JCA and DS. DS is guarantor.

Funding: None.

Competing interests: None declared.

- Mann RA. Acquired flatfoot in adults. *Clin Orthop Rel Res* 1983;181:46-51.
- Johnson KA. Tibialis posterior tendon rupture. *Clin Orthop Rel Res* 1983;177:140-7.
- Haddad FS, Berry G, Singh D, Angel J. Tibialis posterior tendonitis: the forgotten epidemic. Presented at the British Orthopaedic Association, September 1999. *J Bone Joint Surg* 2000;82B(suppl 1):80.
- Chao W, Wapner KL, Lee TH, Adams J, Hecht PJ. Non-operative treatment of posterior tibial tendon dysfunction. *Foot Ankle Internat* 1996;17:736-41.
- Kohls-Gatzoulis JA, Singh D. Tibialis posterior dysfunction as a cause of flatfoot in elderly patients. *Foot* 2004;14:207-9.
- Basmajian JV, Stecko G. The role of muscles in arch support of the foot. *J Bone Joint Surg* 1963;45A:1184-90.
- Myerson MS. Adult acquired flat foot deformity. *J Bone Joint Surg* 1996;78A:780-92.
- Mosier SM, Lucas DR, Pomeroy G, Manoli A II. Pathology of the posterior tibial tendon in posterior tibial tendon insufficiency. *Foot Ankle Int* 1998;19:520-4.
- Frey C, Shereff M, Greenidge N. Vascularity of the posterior tibial tendon. *J Bone Joint Surg* 1990;72A:884-8.
- Mosier SM, Pomeroy G, Manoli A II. Pathoanatomy and aetiology of posterior tibial tendon dysfunction. *Clin Orthop Rel Res* 1999;365:12-22.
- Dyal CM, Feder J, Deland JT, Thompson FM. Pes planus in patients with posterior tibial tendon insufficiency: asymptomatic versus symptomatic foot. *Foot Ankle Int* 1997;18:85-8.

- Kohls-Gatzoulis JA, Singh D, Angel JC. Tibialis posterior insufficiency occurring in a patient without peronei: a mechanical aetiology. *Foot Ankle Int* 2001;22:950-2.
- Mann RA, Thompson FM. Rupture of the posterior tibial tendon causing flat foot. *J Bone Joint Surg* 1985;67A:556-61.
- Yeap JS, Singh D, Birch R. Tibialis posterior tendon dysfunction: a primary or secondary problem? *Foot Ankle Int* 2001;22:51-5.
- Mizel MS, Temple HT, Scranton PE II, Gellman RE, Hecht PJ, Horton GA, et al. Role of the peroneal tendons in the production of the deformed foot with posterior tibial tendon deficiency. *Foot Ankle Int* 1999;20:285-9.
- Monto RR, Moorman CT III, Mallon WJ, Nunley JA II. Rupture of the posterior tibial tendon associated with closed ankle fracture. *Foot Ankle* 1991;11:400-3.
- Borton DC, Saxby TS. Tear of the plantar calcaneonavicular (spring) ligament causing flatfoot. A case report. *J Bone Joint Surg* 1997;79B:641-3.
- Beals TC, Manoli A II. An unusual cause of posterior tibial tendon degeneration. *Foot Ankle Int* 1998;19:177-9.
- Holmes GB II, Mann RA. Possible epidemiological factors associated with rupture of the posterior tibial tendon. *Foot Ankle* 1992;13:70-9.
- Pomeroy GC, Pike RH, Beals TC, Manoli A II. Current concepts review. Acquired flatfoot in adults due to dysfunction of the posterior tibial tendon. *J Bone Joint Surg* 1999;81A:1173-82.
- Myerson M, Solomon G, Shereff M. Posterior tibial tendon dysfunction: its association with seronegative disease. *Foot Ankle* 1989;9:219-25.
- Johnson KA, Strom DE. Tibialis posterior tendon dysfunction. *Clin Orthop Rel Res* 1989;239:196-206.
- Wapner KL, Chao W. Nonoperative treatment of posterior tibial tendon dysfunction. *Clin Orthop Rel Res* 1999;365:39-45.
- Teasdall RD, Johnson KA. Surgical treatment of stage I posterior tibial tendon dysfunction. *Foot Ankle Int* 1994;15:646-8.
- Wacker JT, Hennessy MS, Saxby TS. Calcaneal osteotomy and transfer of the tendon of flexor digitorum longus for stage-II dysfunction of tibialis posterior. Three- to five-year results. *J Bone Joint Surg* 2002;84B:54-8.

(Accepted 14 September 2004)

Lesson of the week

Clomipramine induced neuroleptic malignant syndrome and pyrexia of unknown origin

Alison M Haddow, Dawn Harris, Martin Wilson, Hannah Logie

Neuroleptic malignant syndrome is uncommon. Its major characteristics—classically, fever, muscular rigidity, and raised serum creatinine kinase concentration—occur unpredictably and often in association with dopamine blocking drugs (box).¹ We present a case of neuroleptic malignant syndrome occurring in association with clomipramine, a drug not noted for dopamine blockade. Greater awareness of the possibility of this potentially life threatening syndrome occurring in patients treated with antidepressants may be useful given the continued increase in the prescribing of antidepressants of all classes.

Case report

A 57 year old man—a long term inpatient with frontal lobe dementia in an old age psychiatry ward—was admitted to an acute medical assessment unit in January 2003. He presented with sweating, pyrexia, muscle rigidity, decreased responsiveness, and urinary incontinence (table). At the time of admission he was taking clomipramine and promazine, both started in 2001. He was empirically diagnosed as having urinary tract infection and was prescribed intravenous and then oral antibiotics. He improved and returned to his long stay ward. Urine and blood cultures showed no growth during this admission. In May 2003, his condition deteriorated again with all previous symptoms and signs recurring. At this stage, promazine was stopped

and further medical assessment was requested and again he was diagnosed as having urinary tract infection, and a course of antibiotics was prescribed. In addition to routine investigation, a liver ultrasound was done which showed no abnormality. Once again urine and blood cultures showed no growth. His condition improved, and he was transferred back to his base ward. Later the same month the man's sweating, pyrexia, muscular rigidity, and decreased responsiveness returned. At this stage, an opinion was sought from the department of medicine for the elderly. Due to the length of his history and the lack of a positive microbiological culture, a drug reaction was suspected and his current medication, ciprofloxacin and clomipramine, was stopped. Within 48 hours all symptoms had resolved, and he was provisionally diagnosed as having neuroleptic malignant syndrome. In June 2003 there was a trial reintroduction of clomipramine. After only three doses, however, the previously noted symptoms rapidly recurred again, resolving on withdrawal of the drug. A report was sent to the Committee on Safety of Medicines and the supplier of clomipramine.

Discussion

Pyrexia related to clomipramine has been reported on only four occasions to the Committee on Safety of Medicines, therefore some care was need in labelling

Neuroleptic malignant syndrome can be precipitated by clomipramine and possibly other antidepressants

Royal Cornhill Hospital, Aberdeen AB25 2ZH
Alison M Haddow acting consultant in old age psychiatry
Dawn Harris medical officer

Woodend Hospital, Aberdeen
Martin Wilson specialist registrar in medicine for the elderly
Hannah Logie senior house officer in medicine for the elderly

Correspondence to: A M Haddow alison.haddow@gpct.grampian.scot.nhs.uk

BMJ 2004;329:1333-5